VAS European Book on Angiology/Vascular Medicine
ISBN 978-88-255-1052-2
DOI 104399/978882551052286
pag. 1–9 (maggio 2018)

Circumferential Suction-Assisted Lipectomy is the Only Surgical Procedure that Can Normalize Large Chronic Fat-Transformed Lymphedemas

Håkan Brorson, MD, PhD[1]

1. Introduction

Circumferential suction-assisted lipectomy (CSAL) techniques have proved to be a valuable tool in various aspects of reconstructive surgery. While it is clear that conservative therapies such as complex decongestive therapy (CDT) and controlled compression therapy (CCT) should be tried in the first instance, options for the treatment of late-stage lymphedema that is not responding to this treatment is not so clear. Surgical procedures have been developed and described to address various clinical aspects of the pathophysiology of lymphedema. Microsurgical techniques are promoted to provide physiologic drainage of excessive lymphatic fluid. In many late-stage cases though, adipose tissue deposition and fibrosis are the predominant manifestations of the disease process. Surgical therapies aimed at adipose tissue removal can provide significant symptom relief for affected patients. CSAL enables complete removal of the deposited adipose tissue leading to complete volume reduction both in early and in late stage lymphedema.

2. Is there any evidence for adipose tissue in lymphedema?

Clinicians often believe that the swelling of a lymphedematous extremity is purely due to the accumulation of lymph fluid, which can be removed by the use of noninvasive conservative regimens, such as CDT and CCT. These therapies work well when the excess swelling consists of accumulated lymph, but do not work when the excess volume is dominated by adipose tissue as can be seen in a chronic lymphedema (**Figure 1**).[1] Computer tomography and dual-energy X-ray absorptiometry has shown a high content of adipose tissue in patients with arm lymphedema following breast cancer treatment.[2,3] Recent research shows that chronic inflammation leads to deposition of excess adipose tissue.[4,5] Microsurgical procedures using lymphovenous shunts, lymph vessel transplantation, and vascularized lymph node transfer,[6-10] do not remove adipose tissue; thus complete reduction cannot be achieved with these procedures.

[1] Department of Clinical Sciences, Lund University, Plastic and Reconstructive Surgery, Skåne University Hospital, Lund University, Malmö, Sweden. Håkan Brorson, MD, PhD, Associate Professor (Lund University, Sweden), Professor (Esculera de Graduados, Asociación Médica Argentina, Buenos Aires), Senior Consultant Plastic Surgeon, Department of Clinical Sciences, Lund University, Lymphedema Unit, Plastic and Reconstructive Surgery, Skåne University Hospital, Malmö, Sweden

3. When can CSAL be performed?

Candidates for this procedure are patients who have been optimally treated with conservative therapy and show no or minimal pitting (1–2 mm) (**Figure 2**). Some patients, due ineffective conservative treatment, can show more pitting. As such, some patients selected for CSAL techniques may have some edema present, and in some cases around 4–5 mm of pitting in an arm lymphedema and 6–8 mm in a leg lymphedema can be accepted if the therapist cannot reduce it further. If the presence of edema fluid is the major disease manifestation, the lymphedema must be treated conservatively to transfer it into a non-pitting state, where the excess volume consists of adipose tissue. Extremity volumes are measured and if the excess volume is still troublesome, CSAL is carried out. CSAL should be used as a method to remove fat, not fluid, even if theoretically it could remove the accumulated fluid in a pitting lymphedema without excess adipose tissue formation.

4. Compression garments

Early and continuous compression therapy is imperative to the success of the CSAL protocol. Two custom-made compression garments are measured preoperatively using the healthy arm or leg as a template and one set is put on during surgery.

5. Preoperative investigations

Limb volume measurements are a mainstay evaluation tool in the treatment protocol of lymphedema. Volumes of both extremities are always measured at each visit using water plethysmography, and the difference in volume is designated as the excess volume.[1,11] Particular to the lower extremity, venous color Doppler examination is used to rule out any venous insufficiency, which can influence leg swelling. In addition, the combined occurrence of venous and lymphatic insufficiency is a known entity affecting some patients. Lymphoscintigraphy provides useful information on not only the anatomy, but also on the lymph transport. We use it mostly in patients with primary lymphedema and in patients with unknown leg swelling, for example, when lipedema is suspected.

6. Surgical technique

The use of power-assisted CSAL facilitates the removal of adipose tissue and reduces surgeon-fatigue, particularly in the lower extremity, which can be more demanding to treat. To minimize blood loss, a tourniquet is utilized in combination with tumescence, which involves infiltration of 1–2 L of saline containing low-dose adrenaline and lidocaine.[12,13] Through approximately 15–20 3-4 mm-long incisions, CSAL is performed using 15- and 25-cm-long cannulas with diameters of 3 and 4 mm. When the arm or leg distal to the tourniquet has been treated, a sterilized custom-made compression sleeve and glove is applied to stem bleeding and reduce postoperative edema. The tourniquet is removed and the most proximal part of the upper arm or leg is treated using the tumescent technique.[13] and then the compression sleeve is pulled up to compress the proximal part of the upper arm. The incisions are left open to drain through the sleeve. The aspirate contains 95% fat in mean (**Figure 3**). Operating time is approximately two hours for arms and 3 hours for legs (**Figure 4**).

7. Long term outcome

The techniques to achieve the most desirable results have changed with increasing

experience. Today, chronic non-pitting lymphedema of up to 4.5 L in arms and more than 8 L in legs in excess volume can be effectively removed by use of CSAL (**Figure 5**).[14] Maximal reduction is usually achieved between three and six months. Long-term results have not shown any recurrence of the arm swelling with the permanent use of compression garments (**Figure 6**).[1,11,14,15-18] In addition, promising results can also be achieved for leg lymphedema (**Figure 7**), with maximum reduction usually occurring at around twelve months (**Figure 8**).[19,20]

8. Postoperative regimen: Controlled Compression Therapy

Garments are removed two days postoperatively so that the patient can take a shower. Then, the other set of garments is put on and the used set is washed and dried. The patient repeats this after another two days before discharge. The patient alternates between the two sets of garments, changing them daily so that a clean set is always put on after showering and lubricating the arm. Washing 'activates' the garments by increasing the compression due to shrinkage. The patient is seen after one months when arm volumes are measured.

At the three-month visit, the arm is measured for new custom-made garments. This procedure is repeated at six, nine, and 12 months. When complete reduction is achieved, sleeves without straps are ordered. If complete reduction has been achieved at six months, the nine-month control may be omitted. If this is the case, a quantity sufficient for six months of garments are prescribed, which normally means double the amount that would be needed for three months. When the excess volume has decreased as much as possible—usually the treated arm becomes somewhat smaller than the normal arm—and a steady state is achieved, then new garments can be prescribed using the latest measurements. In this way, the garments are renewed three or four times during the first year. Two sets of sleeve and glove garments are always at the patient's disposal; one is worn while the other is washed. Thus, a garment is worn permanently, and treatment is interrupted only briefly when showering and, possibly, for formal social occasions. The life span of two garments worn alternately is usually 4–6 months. For arms, complete reduction is usually achieved after 3–6 months, often earlier. After the first year, the patient is seen again after six months (1.5 years after surgery) and then at two years after surgery. Then the patient is seen once a year only, when new garments are prescribed for the coming year, which is usually four garments and four gloves (or four gauntlets). For active patients, 6–8 garments and the same amount of gauntlets/gloves a year are needed. Patients without preoperative swelling of the hand can usually stop using the glove/gauntlet after 6–12 months postoperatively.

For legs we use up to two or three compression garments on top of each other, depending on what is needed to prevent pitting. A typical example is compression class 3 with a panty, on top of this, a leg long garment, compression class 2, and a below-the-knee garment, compression class 2. Thus, such a patient needs two sets of 2–3 garments. Depending on the age and activity of the patient, two such sets can last for 2–4 months. That means that they must be prescribed 3–6 times during the first year. After complete reduction has been achieved, no panty is needed and stay-up garments are ordered, and the patient is seen once a year when all new garments are prescribed for the coming year.

Summary

- Excess volume without pitting means that adipose tissue is responsible for the swelling.
- As in conservative treatment, the lifelong use (24 h a day) of compression garments is mandatory for maintaining the effect of treatment. Since all patients comply with this before surgery nothing new is added.
- Adipose tissue can be removed with CSAL. Conservative treatment and microsurgical reconstructions cannot do this, thus CSAL in the only surgical method to achieve complete reduction of the excess volume of the lymphedematous limb.

References

1. Brorson H, Svensson H. Liposuction combined with controlled compression therapy reduces arm lymphedema more effectively than controlled compression therapy alone. Plast Reconstr Surg 1998;102:1058–67. Discussion 1068.
2. Brorson H, Ohlin K, Olsson G, et al. Adipose tissue dominates chronic arm lymphedema following breast cancer: an analysis using volume rendered CT images. Lymphat Res Biol 2006;4:199–210.
3. Brorson H, Ohlin K, Olsson G, et al. Breast cancer-related chronic arm lymphedema is associated with excess adipose and muscle tissue. Lymphat Res Biol 2009;7:3–10.
4. Zampell JC, Aschen S, Weitman ES, et al. Plast Reconstr Surg 2012;129:825–34.
5. Aschen S, Zampell JC, Elhadad S, et al. Regulation of adipogenesis by lymphatic fluid stasis: part II. Expression of adipose differentiation genes. Plast Reconstr Surg 2012;129:838–47.
6. Baumeister RG, Siuda S. Treatment of lymphedemas by microsurgical lymphatic grafting: what is proved?. Plast Reconstr Surg 1990;85:64–74. Discussion 75–6.
7. Baumeister RG, Frick A. The microsurgical lymph vessel transplantation. Handchir Mikrochir Plast Chir 2003;35:202–9.
8. Campisi C, Davini D, Bellini C, et al. Lymphatic microsurgery for the treatment of lymphedema. Microsurgery 2006;26:65–9.
9. Saaristo AM, Niemi TS, Viitanen TP, et al. Microvascular breast reconstruction and lymph node transfer for postmastectomy lymphedema patients. Ann Surg 2012;255:468–73.
10. Viitanen TP, Visuri MP, Hartiala P, et al. Lymphatic vessel function and lymphatic growth factor secretion after microvascular lymph node transfer in lymphedema patients. Plast Reconstr Surg – Global Open 2013;1:1–9.
11. Brorson H, Svensson H. Complete reduction of lymphoedema of the arm by liposuction after breast cancer. Scand J Plast Reconstr Surg Hand Surg 1997;31:137–43.
12. Klein JA. The tumescent technique for liposuction surgery. Am J Cosm Surg 1987;4:263–7.
13. Wojnikow S, Malm J, Brorson H. Use of a tourniquet with and without adrenaline reduces blood loss during liposuction for lymphoedema of the arm. Scand J Plast Reconstr Surg Hand Surg 2007;41:243–9.
14. Brorson H, Svensson H, Norrgren K, et al. Liposuction reduces arm lymphedema without significantly altering the already impaired lymph transport. Lymphology 1998;31:156–72.
15. Brorson H. Liposuction in arm lymphedema treatment. Scand J Surg 2003;92:287–95.
16. Brorson H, Ohlin K, Olsson G, et al. Quality of life following liposuction and conservative treatment of arm lymphedema. Lymphology 2006;39:8–25.
17. Brorson H, Svensson H. Skin blood flow of the lymphedematous arm before and after liposuction. Lymphology 1997;30:165–72.

18. Brorson H, Ohlin K, Olsson G, et al. Liposuction of postmastectomy arm lymphedema completely removes excess volume: a thirteen year study (Quad erat demonstrandum). Eur J Lymphol 2007;17:9.
19. Brorson H, Freccero C, Ohlin K, et al. Liposuction normalizes elephantiasis of the leg. A prospective study with a 6 years follow up. Eur J Lymphol 2009;20:29.
20. Brorson H, Ohlin K, Svensson B, et al. Controlled compression therapy and liposuction treatment for lower extremity lymphedema Lymphology 2008;41:52–63.

Figure 1. Transection of a normal (left) and a lymphedematous arm (right) showing the abundance of adipose tissue. (Courtesy: Dr C-H Håkansson, Department of Oncology, Lund University Hospital)

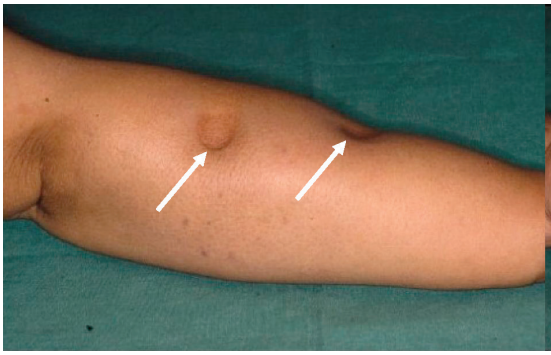

Figure 2a. Marked lymphedema of the arm after breast cancer treatment, showing pitting several centimeters in depth (stage I edema). The arm swelling is dominated by the presence of fluid, i.e. the accumulation of lymph.

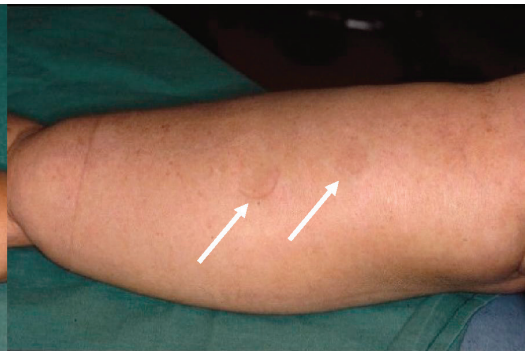

Figure 2b. Pronounced arm lymphedema after breast cancer treatment (stage II-III edema). There is no pitting in spite of hard pressure by the thumb for one minute. A slight reddening is seen at the two spots where pressure has been exerted. The 'edema' is completely dominated by adipose tissue. The term 'edema' is improper at this stage since the swelling is dominated by hypertrophied adipose tissue and not by lymph. At this stage, the aspirate contains either no, or a minimal amount of lymph.

Figure 3. The aspirate contains 90–100% adipose tissue in general. This picture shows the aspirate collected from the lymphedematous arm of the patient shown in *Figures 4, 5,* and *7* before removal of the tourniquet. The aspirate sediments into an upper adipose fraction (90%) and a lower fluid (lymph) fraction (10%).

Figure 4. Liposuction of arm lymphedema. The procedure takes about two hours. From preoperative to postoperative state (left to right). Note the tourniquet, which has been removed at the right, and the concomitant reactive hyperemia.

Figure 5a. A 74-year-old woman with a non-pitting arm lymphedema for 15 years. Preoperative excess volume is 3090 ml.

Figure 5b. Postoperative result at one year with complete reduction.

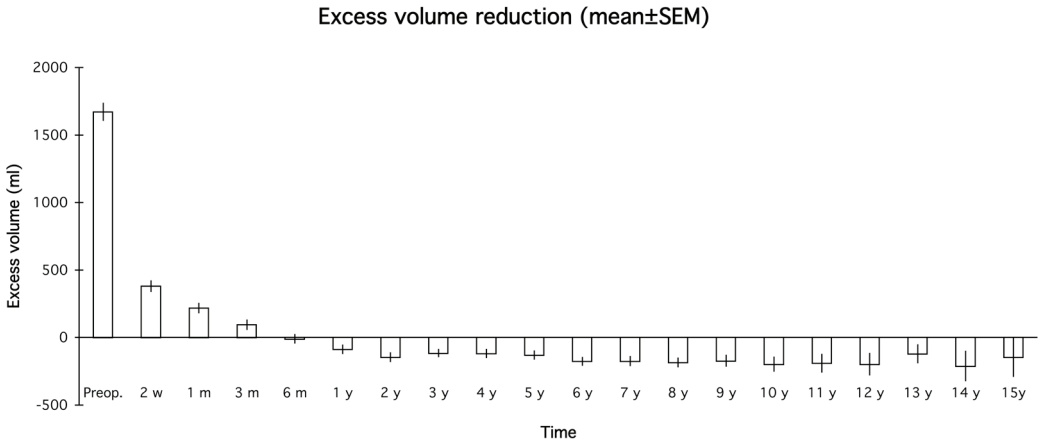

Figure 6. Mean (± SEM) postoperative excess volume reduction in 124 women with arm lymphedema following breast cancer.

Figure 7. Primary lymphedema: Preoperative excess volume 6630ml (left). Postoperative result after two years (right).

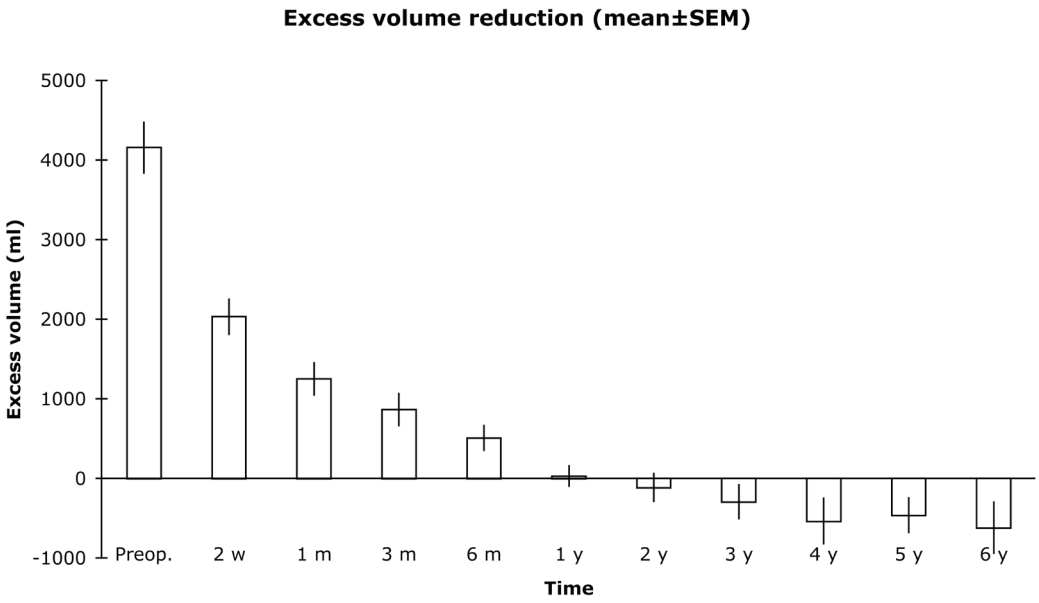

Figure 8. Mean (± SEM) postoperative excess volume reduction in 44 patients with primary or secondary leg lymphedema.